

Case of Dysgerminoma with Partial Deletion of X Chromosome

Vali Faraz¹, Dave Pariseema^{2a}, Patel Bijal^{2b}


Fellow¹, Professor^{2a, b}

Department of Gynaecology Oncology,

The Gujarat Cancer & Research Institute, Asarwa, Ahmednagar, Gujarat, India

Corresponding author: pariseema.dave@gcriindia.org

 ^{2a}<https://orcid.org/0000-0003-3300-4414>

 ^{2b}<https://orcid.org/0000-0002-5446-1959>

Summary

A 22 year old female presented with pain and distension of abdomen. She had not attained menarche and was having primary infertility. She was short stature. Her breasts were under developed but axillary and pubic hair development was normal. On examination there was huge, hard, fixed mass in lower abdomen with restricted mobility. On imaging, there was solid irregular mass in pelvis with hypoplastic uterus. LDH and beta hCG levels were raised. Biopsy of the mass with immunohistochemistry revealed dysgerminoma. Karyotype revealed 46 X, del X (p21), absence of Y component. There were no stigmata of Turner syndrome. On endocrine evaluation she had hypergonadotropic hypogonadism and no autoimmune disorders. Because of the mass being unresectable, she underwent one cycle chemotherapy followed by laparotomy. There was right ovarian mass and other ovary was streak with small uterus, so she underwent hysterectomy and bilateral salpingoophorectomy with unilateral pelvic lymphadenectomy. Post surgery she was given three cycles of chemotherapy and was kept on estrogen replacement therapy. Patient is on 3 monthly follow up. This case highlights the importance of doing karyotyping in case of premenarcheal females with pelvic mass.

Keywords: Dysgerminoma, Turner syndrome, karyotype

Introduction

Approximately 5% of dysgerminomas are diagnosed in women (phenotypic) with dysgenetic gonads.¹⁻³ Here we present a case of dysgerminoma in female with partial deletion of X chromosome.

Case report

A 22 year old female from lower socioeconomic class presented to our hospital with abdominal distension and pain for ten days. She had not attained menarche. She was married for 2 years and was unable to conceive. On general examination height was 146 cm (Adjusted mid parental height= $(F-13) + M / 2 = 156.5 \pm 8.5$, F- father's height, M-mother's height) which was less than 3rd centile. Thus, patient was short stature. Bilateral breasts were underdeveloped (Tanner stage 3) while axillary and pubic hair were well developed (Tanner stage 4). On abdominal examination there was a single, hard, irregular mass felt in lower abdomen up to umbilicus with restricted mobility, no ascites; on vaginal examination vaginal length was normal and cervix was felt higher up; on rectal examination there was a

hard, fixed, irregular mass dissecting rectovaginal septum and compressing rectum, rectal mucosa was free, uterus was not felt separately.

Transabdominal ultrasonography (USG) and MRI pelvis revealed 15 x 10 cm large multilobulated solid lesion in pelvis encasing left lower ureter with proximal hydroureter and hydronephrosis. Hypoplastic uterus like structure was seen. On contrast enhanced CT (CECT) scan there was no lymphadenopathy and urinary tract was normal. LDH and beta hCG were raised (1844 U/l and 35 IU/L respectively). AFP was normal (1.36 ng/ml). Biopsy from the lesion was done because the mass was unresectable and it revealed malignant germ cell tumor. Immunohistochemistry (PLAP +, OCT3/4 +, C-kit/CD117 +, CD30 -) confirmed Dysgerminoma. Karyotype report was 46 X, del X (p21), absence of Y component, although mosaicism couldn't be ruled out [Figure 1]. On endocrine evaluation, FSH and LH were raised (134 mIU/ml and 68 mIU/ml respectively), estradiol and Anti-mullerian hormone were reduced (<5 pg/ml and <0.01 respectively) while prolactin and TSH were normal. 2D echo was done to rule out coarctation of aorta. There was no skeletal anomaly.

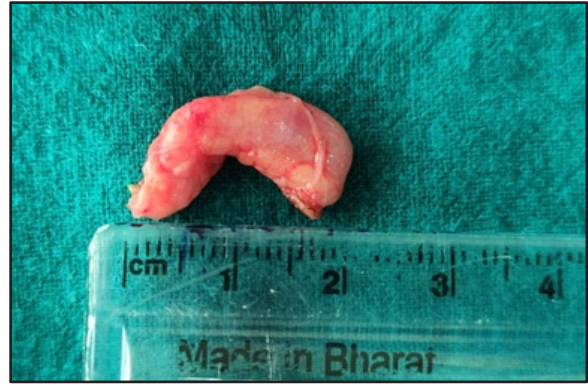In multidisciplinary tumor board discussion it was decided to administer one cycle neoadjuvant chemotherapy followed by evaluation for surgery because the mass was unresectable. After


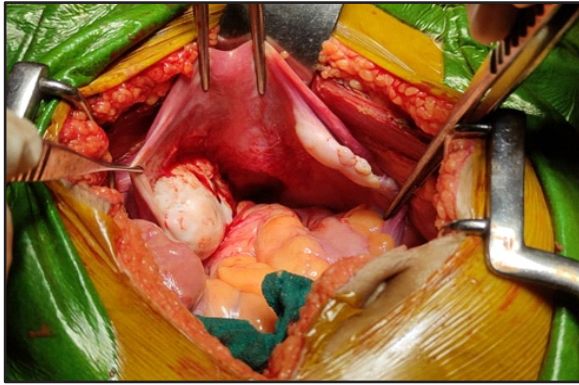
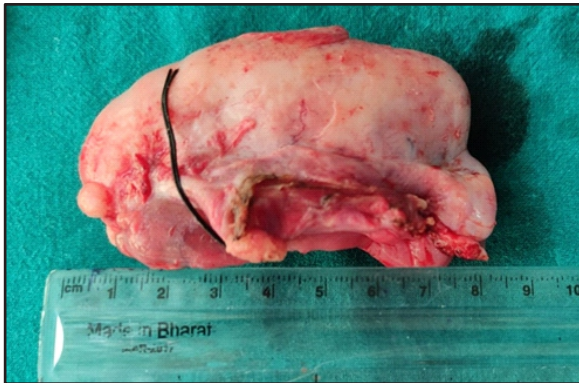

Figure 1: Karyotype: Deletion of short arm of chromosome X



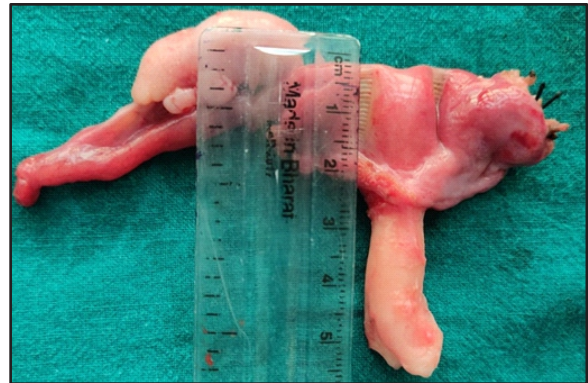(a) Left sided ovarian mass and right sided streak ovary



(b) Right sided streak ovary



(c) Left ovarian mass



(d) Hypoplastic uterus

Figure 2: Intraoperative findings

one cycle of chemotherapy BEP (Bleomycin, Etoposide, Ciplatin) patient was re-evaluated. On examination size of the mass was reduced. CECT scan showed 10 x 9 cm solid mass in pelvis with loss of fat plane with sigmoid, no abnormality in bilateral lungs. LDH and beta hCG levels were reduced (190 U/l and 4.5 IU/L respectively). As there was reduction in size of mass and LDH and beta hCG levels she underwent laparotomy. Patient and her husband were counselled preoperatively regarding need for removal of another ovary and uterus because there is 10 - 15 % rate of bilaterality in dysgerminoma,⁴ ovaries were non-functional and uterus was hypoplastic. Intraoperative findings: no ascites, uterus was small, 5x4cm left ovarian mass adherent in pouch of douglas with sigmoid colon and posterior wall of uterus, right ovary was atrophic with nodular growth over it, bilateral fallopian tubes were normal, no disease elsewhere in abdomen [Figure 2]. She underwent removal of left ovarian mass, right salpingo oophorectomy, hysterectomy, infracolic omentectomy and left sided pelvic lymphadenectomy. Her histopathology report revealed microscopic foci of residual dysgerminoma in left ovary while right ovary was streak gonad and no disease in omentum and lymphnodes.

Patient was discharged on 5th post-operative day. Patient received three cycles of BEP chemotherapy postoperatively at 21 days intervals.

She was started on estrogen replacement therapy. She is on three monthly follow up with clinical examination, USG and LDH for two years.

Discussion

There are various abnormalities of X chromosome e.g. complete deletion, partial deletion, ring X and isochromosome of the long arm of the X chromosome (i[Xq]). Our patient is a case of partial deletion of X chromosome, specifically short arm p21. The effective monosomy created by the deletion of Xp is thought to lead to some of the phenotypic features of Turner syndrome.⁵ The short stature homeobox (SHOX) gene is located in the distal region of Xp and its deletion is directly associated with short stature and skeletal deformities. Deletion of short arm of X chromosome is associated with decreased chances of menstruation and fertility. Our patient had short stature, underdeveloped breasts, primary amenorrhea and infertility. She also had streak ovary and hypoplastic uterus. There were no other features of Turner syndrome.

Dysgerminoma is the most common (i.e. 30 – 40 %) malignant germ cell tumor and 75 % occur between 10 to 30 years of age.^{1,6,7} It can be associated with pure gonadal dysgenesis, mixed gonadal dysgenesis or androgen insensitivity syndrome. Presence of Y chromosome increases the risk of

development of gonadoblastoma and dysgerminoma. However, in one study involving 29 patients of Turner syndrome with Y chromosome, there was not a single case of gonadoblastoma which suggests that there may be lower risk of ovarian germ cell tumors than previously estimated.⁸ The presence of Y material was ruled out in our patient.

There are few reports of dysgerminoma developing in patients with partial monosomy X and dysgenetic gonads.⁹ Therefore, for the development of germ cell tumor it is not mandatory to have monosomy X.

In most of the cases of gonadal dysgenesis, dysgerminomas arise in gonadoblastomas. More than 50% gonadoblastoma in gonadal dysgenesis will develop into ovarian malignancies if not excised.³

However, in our patient there was no evidence of gonadoblastoma in the excised specimen.

Thus, our study highlights the importance of doing karyotype in premenarcheal patients with a pelvic mass.

References

1. Scully RE, Young RH, Clement PB: Tumors of the ovary, maldeveloped gonads, fallopian tube, and broad ligament. In: Atlas of Tumor Pathology. Washington, DC: Armed Forces Institute of Pathology; 1998: Fascicle 23, 3rd series
2. Obata NH, Nakashima N, Kawai M, et al: Gonadoblastoma with dysgerminoma in one ovary and gonadoblastoma with dysgerminoma and yolk sac tumor in the contralateral ovary in a girl with 46XX karyotype. *Gynecol Oncol* 1995; 58:124-128
3. Bremer GL, Land JA, Tiebosch A, et al: Five different histologic subtypes of germ cell malignancies in an XY female. *Gynecol Oncol* 1993; 50:247-248
4. Jonathan S. Berek, Diana P. English, Teri A. Longacre, Michael Friedlander; Ovarian, fallopian tube and peritoneal cancer; pg 2381, Berek & Novak's gynaecology; 16th edition
5. Leppig KA, Distche CM: Ring X and other structural X chromosome abnormalities: X inactivation and phenotype. *Semin Reprod Med* 2001; 19:147-157
6. Berek JS, Friedlander M, Hacker NF: Epithelial ovarian, fallopian tube and peritoneal cancer. In: Berek JS, Hacker NF. Berek and Hacker's Gynecologic Oncology. 6th ed. Philadelphia, PA: Wolters Kluwer; 2015:464-529
7. Kurman RJ, Scardino PT, Waldmann TA, et al: Malignant germ cell tumors of the ovary and testis: An immunohistologic study of 69 cases. *Ann Clin Lab Sci* 1979; 9:462-466
8. Hasle H, Olsen JH, Nielsen J, Hansen J, Friedrich U, Tommerup N: Occurrence of cancer in women with Turner syndrome. *Br J Cancer* 1996; 73:1156-1159
9. Sathiapalan RK, Kao Y, Yu LC: Dysgerminoma in a patient with partial deletion of x chromosome. *Annals of Saudi Medicine* 2000; 20:285-287